


Pharmacology and therapeutics

Female pattern hair loss: a pilot study investigating combination therapy with low-dose oral minoxidil and spironolactoneRodney D. Sinclair^{1,2}, MBBS, MD, FACD ¹Epworth Hospital, East Melbourne, Vic., Australia, and ²Sinclair Dermatology Clinical Trial Centre, East Melbourne, Vic., Australia**Correspondence**Rodney D. Sinclair, MBBS, MD, FACD
Epworth Hospital
East Melbourne, Vic.
Australia
E-mail: rodney.sinclair@
epworthdermatology.com.au

Funding: None.

Conflicts of interest: Rodney Sinclair holds Innovation Patent 2011100917 entitled Treatment of male and female androgenetic alopecia with oral minoxidil either alone or in combination with antiandrogens on 18 August 2011.

Abstract**Background** Minoxidil and spironolactone are oral antihypertensives known to stimulate hair growth.**Objective** To report on a case series of women with pattern hair loss (PHL) treated with once daily minoxidil 0.25 mg and spironolactone 25 mg.**Methods** Women newly diagnosed with a Sinclair stage 2–5 PHL were scored for hair shedding and hair density before and after 12 months of treatment with oral minoxidil 0.25 mg and spironolactone 25 mg.**Results** A total of 100 women were included in this observational pilot study. Mean age was 48.44 years (range 18–80). Mean hair loss severity at baseline was Sinclair 2.79 (range 2–5). Mean hair shedding score at baseline was 4.82. Mean duration of diagnosis was 6.5 years (range 0.5–30). Mean reduction in hair loss severity score was 0.85 at 6 months and 1.3 at 12 months. Mean reduction in hair shedding score was 2.3 at 6 months and 2.6 at 12 months. Mean change in blood pressure was –4.52 mmHg systolic and –6.48 mmHg diastolic. Side effects were seen in eight women but were generally mild. No patients developed hyperkalemia or any other blood test abnormality. Six of these women continued treatment, and two women who developed urticaria discontinued treatment.**Limitations** Prospective, uncontrolled, open-label observational study.**Discussion** Once daily capsules containing minoxidil 0.25 mg and spironolactone 25 mg appear to be safe and effective in the treatment of FPHL. Placebo-controlled studies to investigate this further are warranted.**Capsule summary**

- Oral minoxidil is an antihypertensive that causes hypertrichosis.
- Spironolactone is a diuretic with antiandrogen properties used in the treatment of female pattern hair loss.
- One hundred women with female pattern hair loss were treated off-label with extemporaneously formulated oral capsules containing minoxidil 0.25 mg and spironolactone 25 mg.
- Mean reduction in hair loss severity score was 0.85 at 6 months and 1.3 at 12 months. Mean reduction in hair shedding score was 2.3 at 6 months and 2.6 at 12 months.
- Side effects were seen in eight patients and included postural hypotension, hypertrichosis, and urticaria.

Introduction

104 Female pattern hair loss (FPHL) is one of the most common causes of hair loss encountered in clinical practice.¹ FPHL is a

complex polygenic disorder^{2–5} characterized clinically by diffuse hair thinning over the midfrontal scalp⁶ and increased hair shedding.⁷ Histologically, the hallmark is site-specific hair follicle miniaturization.⁸ Site specificity may result from epigenetic modification of the androgen receptor gene.⁹ The proportion of miniaturized follicles increases with the severity of hair loss.¹⁰ Age-related, so-called senescent alopecia also shows hair follicle miniaturization and is indistinguishable from FPHL.¹¹ FPHL adversely impacts on quality of life.¹² FPHL is progressive, and the risk, prevalence, and severity of FPHL increase with age.¹³ In a population study of over 700 women, FPHL, defined as \geq Sinclair stage 2, was found in 12% of women aged 20–29 and 57% of women aged ≥ 80 . Severe hair loss, defined as Sinclair stages 3, 4, and 5, increased from 4% among women aged 20–29 years to 30% among women aged ≥ 80 years. In addition, some women present with increased hair shedding but no clinical evidence of FPHL. Approximately 60% of these women will have histological evidence of androgenetic alopecia on scalp biopsy with a terminal to vellus hair ration $\leq 4 : 1$.¹⁴

Hair follicle miniaturization is potentially reversible initially but eventually becomes irreversible.^{15–17} One hypothesis to explain irreversible hair follicle miniaturization is the observed replacement of the proximal arrector pili muscle by adipose tissue disrupting the stem cell niche at the hair follicle bulge.^{17,18} Fatty degeneration of the arrector muscle is not seen in alopecia areata where hair follicle miniaturization is potentially reversible.¹⁸ Treatment is likely to be most successful in women with early female pattern hair loss.¹⁹

While scalp biopsy may be required to identify histological features of androgenetic alopecia in women with early FPHL and differentiate this condition from chronic telogen effluvium,²⁰ dermoscopy is a valuable alternative and shows a reduction in the number of secondary hair fibers emerging from each pore over the affected region of the scalp.^{17,21}

A number of agents have also been used in the treatment of female pattern hair loss including the androgen receptor antagonists spironolactone, cyproterone acetate,¹⁹ and flutamide²² as well as the 5 α reductase antagonist finasteride²³ and dutasteride. These agents can be used either alone or in combination with topical minoxidil.²⁴

Minoxidil is a piperidinopyrimidine derivative and a potent vasodilator that is effective orally for severe hypertension. When applied topically, minoxidil has been shown to arrest hair loss or to induce mild to moderate hair regrowth in approximately 60% of women with FPHL.²⁵ A clinical trial comparing 5% and 2% formulations of minoxidil found a mean increase in nonvellus hair counts after 48 weeks of 18% and 14%, respectively.²⁶ Topical minoxidil was approved by the FDA in 1992 for the treatment of female pattern hair loss. It appears to be a safe therapy with side effects only of local irritation and hypertrichosis of the temples,

and there is a low incidence of contact dermatitis.²⁷ If treatment is stopped, clinical regression occurs within 6 months, to the state of baldness that would have existed if treatment had not been applied.²⁸ For patients to maintain any beneficial effect, applications must continue indefinitely.

Spironolactone is an aldosterone antagonist and has been used as a potassium-sparing diuretic for over 50 years. It is structurally a steroid, with basic steroid nuclei with four rings. Its primary metabolite, canrenone, is the active antagonist of aldosterone and contributes to the diuretic action. The ingested drug is absorbed rapidly and metabolized by the liver to canrenone and potassium canrenoate. The drug is available in 25 and 100 mg tablets. No dermatologic indications for spironolactone have been approved by the FDA; however, it is widely used off-label in the treatment of FPHL²⁹ and has been shown to arrest progression in over 90% of women. In addition, approximately, 30% of women demonstrate improved standardized scalp photographic assessment.¹⁹

Hair transplantation surgery is a highly effective treatment for male pattern hair loss. For women surgical options are limited. Most women with FPHL also have reduced hair density over the occipital scalp, reducing the yield from hair transplant surgery.

We report the results of a prospective, uncontrolled observational study of the safety and usefulness of a single, once daily low-dose oral minoxidil in combination with spironolactone in the treatment of FPHL.

Materials and methods

Women with a Sinclair stage 2–5 female pattern hair loss were offered treatment with a single once daily capsule containing minoxidil 0.25 mg together with spironolactone 25 mg. For

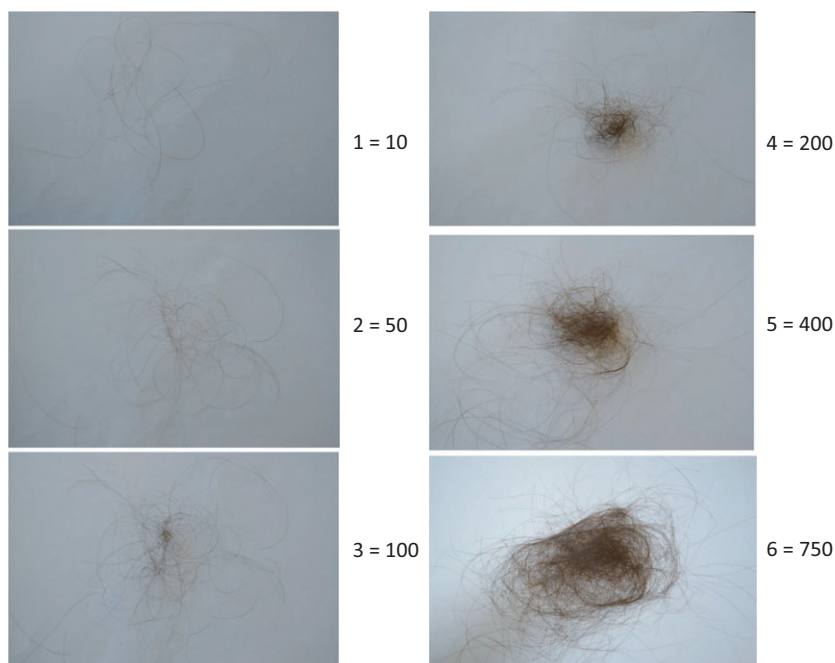


Figure 1 Sinclair hair shedding scale. Patients were asked how much hair they shed in a single day. As hair shedding is usually worse after washing, that score was documented

women with a baseline blood pressure $\leq 90/60$ or a history of postural hypertension or fainting, 50 mg of sodium chloride was added to the capsule. Hair shedding was scored using a six-point visual analogue scale (Fig. 1). Hair density was scored using the 5 stage Sinclair scale (Fig. 2). Women were reviewed at 3 monthly intervals. Blood pressure was recorded at each visit, and patients were specifically questioned about the presence of unwanted facial or body hair at each follow-up visit and any other side effects.

Full blood count, renal function, electrolytes, and liver function testing were performed at baseline and at 3 monthly intervals.

Results

One hundred women with newly diagnosed Sinclair stage 2–5 female pattern hair loss were treated with a once daily capsule containing minoxidil 0.25 mg and spironolactone 25 mg and followed prospectively for 12 months.

The mean age was 48.44 years (range 18–80). Mean hair loss severity at baseline was Sinclair 2.79 (range 2–5). The mean hair shedding score at baseline was 4.82 (range 1–6). Mean duration of diagnosis was 6.5 years (range 0.5–30).

Side effects were seen in eight women but were generally mild. Side effects included urticaria (2), postural hypotension (2), and facial hypertrichosis (4). No patients developed hyperkalemia or any other blood test abnormality. Six of these women continued treatment, and two women who developed urticaria discontinued treatment.

Baseline mean systolic blood pressure was 122.92 mmHg. Baseline mean diastolic pressure was 79.17 mmHg. Follow-up blood pressure after 3 months was 118.40 systolic and 72.69 diastolic. Mean change in systolic blood pressure was -4.52 mmHg. Mean change in diastolic blood pressure was -6.48 . Two patients developed symptoms of postural hypotension necessitating introduction of 50 mg daily of sodium chloride.

Four patients reported hypertrichosis. This was managed by a combination of plucking (1) or waxing (3).

A temporary increase in hair shedding 3–6 weeks following initiation of treatment was anticipated. Twenty-two patients reported this shedding as being of significant concern. All patients had been prewarned about the possibility of a temporary increase in hair shedding on initiation of therapy and advised to continue treatment. No women discontinued the treatment as a result of increased hair shedding following commencement of therapy. For 16 women, this shedding ceased within 4 weeks, while for four women it persisted for more than 6 weeks and for two women, it persisted for more than 12 weeks.

Two patients ceased the medication because of urticaria that was presumed to be related to the spironolactone. The urticaria settled within 7 days of cessation and did not recur when the minoxidil was recommenced as monotherapy.

Mean hair loss severity at baseline was Sinclair 2.79 (range 2–5). Mean hair shedding score at baseline was 4.82 (range 1–6).

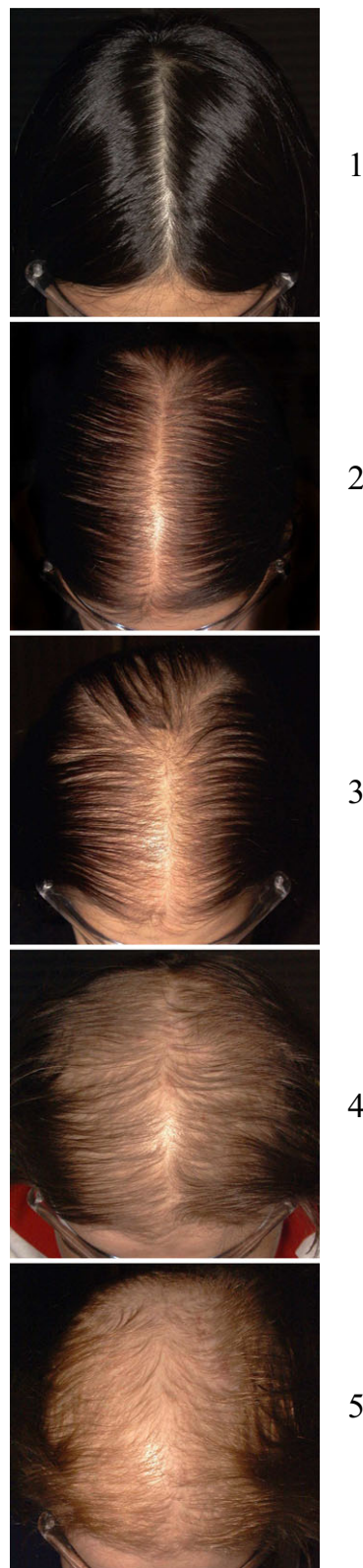


Figure 2 Sinclair hair loss severity scale for female pattern hair loss

Patient 1



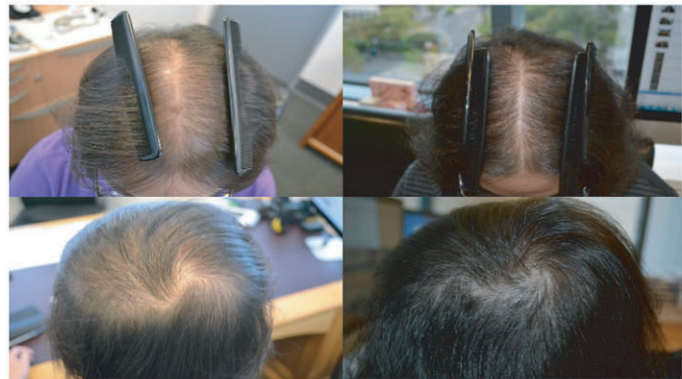Patient 2



Patient 3



Patient 4



Patient 5

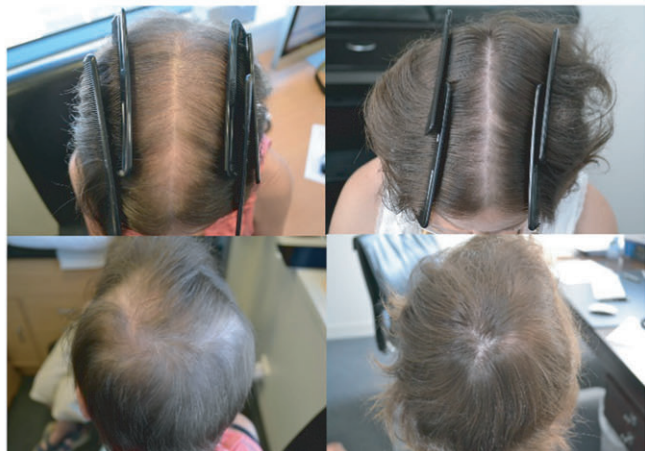

Figure 3 Before and after 12-month therapy

Mean reduction in hair loss severity score was 0.1 at 3 months, 0.85 at 6 months, 1.1 at 9 months, and 1.3 at 12 months (Fig. 3). Mean reduction in hair shedding score was 1.1 at 3 months, 2.3 at 6 months, 2.7 at 9 months, and 2.6 at 12 months.

Discussion

Oral minoxidil was approved by the FDA for the treatment of hypertension in 1979. It was first noticed to improve hair loss in male androgenetic alopecia in 1980.³⁰ Topical minoxidil received FDA approval for male androgenetic alopecia in 1988 and for female pattern hair loss in 1992.

Oral minoxidil is not often used in the treatment of AGA, largely because of the side-effect profile seen at standard doses.

Our women's hair loss clinic was established in 1995 and currently treats over 750 women with FPHL. The mainstay of therapy was an oral antiandrogen such as cyproterone acetate or spironolactone used either alone¹⁹ or together with topical minoxidil.³¹ Over the years, we had accumulated a number of women in our clinic who were either not satisfied with the results achieved by conventional therapy, or who were intolerant of topical minoxidil. Intolerance was either because of scalp irritation or altered hair texture. Oral minoxidil is available in Australia as 10 mg tablets. Off-label use of a half or quarter tablet of oral minoxidil led to noticeable improvement in hair density in most of these women but was complicated by postural hypotension, fluid retention, and hypertrichosis. While fluid retention can often be managed by the addition of spironolactone, this has the potential to increase postural hypotension.

As minoxidil side effects are all dose related, we compounded oral minoxidil extemporaneously into capsules containing 0.25 mg or one-fortieth of a tablet.

To reduce the risk of fluid retention and to augment therapy by the addition of an oral antiandrogen, spironolactone 25 mg was added to the capsule. For women with low blood pressure, 50 mg of sodium chloride was also added to the capsule. The combination of spironolactone and minoxidil is likely to have an additive benefit in FPHL.³¹

Low-dose oral minoxidil was well tolerated in the majority of our patients with FPHL and is a reasonable alternative in women intolerant of or unwilling to use topical minoxidil. While hyperkalemia, creatinine elevation, and hepatitis are reported with spironolactone,³² we did not encounter any hematological abnormalities at the dose used in this study.

Most women noticed a reduction in hair shedding at 3 months and an increase in hair density at 6 months.

References

- Messenger AG, de Berker DAR, Sinclair RD. Disorders of hair. In: Burns T, Breathnach S, Cox N, Griffiths C, eds. *Rook's Textbook of Dermatology*, 8th edn. Oxford: Wiley-Blackwell, 2012: 66.1–66.101.
- Yip L, Zaloumis S, Irwin D, et al. Association analysis of oestrogen receptor beta gene (ESR2) polymorphisms with female hair loss. *Br J Dermatol* 2012; **166**: 1131–1134.
- Yip L, Zaloumis S, Irwin D, et al. Gene-wide association study between the aromatase gene (CYP19A1) and female pattern hair loss. *Br J Dermatol* 2009; **161**: 289–294.
- Harrison S, Ellis JA, Sinclair R, et al. Genetic analysis of the androgen receptor gene in female pattern hair loss. *Br J Dermatol* 2004; **151**(Suppl 65): 7.
- Redler S, Brockschmidt FF, Tazi-Ahni R, et al. Investigation of the male pattern baldness major genetic susceptibility loci AR/EDA2R and 20p11 in female pattern hair loss. *Br J Dermatol* 2012; **166**: 1314–1318.
- Olsen EA. The midline part: an important physical clue to the clinical diagnosis of androgenetic alopecia in women. *J Am Acad Dermatol* 1999; **40**: 106–109.
- Sinclair R. Hair shedding in women: how much is too much? *Br J Dermatol* 2015; **173**: 846–848.
- Whiting D. Diagnostic and predictive value of horizontal sections of scalp biopsy specimens in male pattern androgenetic alopecia. *J Am Acad Dermatol* 1993; **28**: 755–763.
- Cobb JE, Wong NC, Yip LW, et al. Evidence of increased DNA methylation of the androgen receptor gene in occipital hair follicles from men with androgenetic alopecia. *Br J Dermatol* 2011; **165**: 210–213.
- Messenger AG, Sinclair RD. Follicular miniaturization in female pattern hair loss: clinicopathological correlations. *Br J Dermatol* 2006; **155**: 926–930.
- Sinclair R, Magee J, Chapman A. The lack of significant changes in scalp hair follicle density with advancing age. *Br J Dermatol* 2005; **152**: 646–649.
- Biondo S, Sinclair R. Quality of life in Australian women with female pattern hair loss. *Open Dermatol J* 2010; **4**: 90–94.
- Gan DC, Sinclair RD. Prevalence of male and female pattern hair loss in maryborough. *J Investig Dermatol Symp Proc* 2005; **10**: 184–189.
- Sinclair R, Jolley D, Mallari R, et al. The reliability of horizontally sectioned scalp biopsies in the diagnosis of chronic telogen hair loss in women. *J Am Acad Dermatol* 2004; **51**: 189–199.
- Yazdabadi A, Magee J, Harrison S, et al. The Ludwig pattern of androgenetic alopecia is due to a hierarchy of androgen sensitivity within follicular units that leads to selective miniaturization and a reduction in the number of terminal hairs per follicular unit. *Br J Dermatol* 2008; **159**: 1300–1302.
- Yazdabadi A, Whiting D, Rufaut NW, et al. Miniaturized hairs maintain contact with the arrector pili muscle in alopecia areata but not in androgenetic alopecia: a model for reversible miniaturization and potential for regrowth. *Int J Trichology* 2012; **4**: 154–156.
- Sinclair R. Winding back the clock on female androgenetic alopecia. *Br J Dermatol* 2012; **167**: 1157–1158.
- Torkamani N, Rufaut NW, Jones L, et al. Destruction of the arrector pili muscle and fat infiltration in androgenic alopecia. *Br J Dermatol* 2014; **170**: 1291–1298. <https://doi.org/10.1111/bjd.12921>.
- Sinclair R, Wewerinke M, Jolley D. Treatment of female pattern hair loss with oral antiandrogens. *Br J Dermatol* 2005; **152**: 466–473.
- Sinclair R. Chronic telogen effluvium: a study of 5 patients over 7 years. *J Am Acad Dermatol* 2005; **52**: S12–S16.

- 21 Sperling L, El Shabrawi Caelen L, Sinclair R. *Alopecias*. Bologna: Ed Dermatology, 2012.
- 22 Yazdabadi A, Sinclair R. Treatment of female pattern hair loss with the androgen receptor antagonist flutamide. *Australas J Dermatol* 2011; **52**: 132–134.
- 23 Thai KE, Sinclair RD. Finasteride for female androgenetic alopecia. *Br J Dermatol* 2002; **147**: 812–813.
- 24 Hoedemaker C, van Egmond S, Sinclair R. Treatment of female pattern hair loss with a combination of spironolactone and minoxidil. *Australas J Dermatol* 2007; **48**: 43–45.
- 25 De Villez RL, Jacobs JP, Szpunar CA, *et al*. Androgenetic alopecia in the female. Treatment with 2% topical minoxidil solution. *Arch Dermatol* 1994; **130**: 303–307.
- 26 Lucky AW, Piacquadio DJ, Ditre CM, *et al*. A randomized, placebo-controlled trial of 5% and 2% topical minoxidil solutions in the treatment of female pattern hair loss. *J Am Acad Dermatol* 2004; **50**: 541–553.
- 27 Tosti A, Bardazzi F, De Padova MP, *et al*. Contact dermatitis to minoxidil. *Contact Dermatitis* 1985; **13**: 275–276.
- 28 Olsen EA, DeLong ER, Weiner MS. Long-term follow-up of men with male pattern baldness treated with topical minoxidil. *J Am Acad Dermatol* 1987; **16**: 688–695.
- 29 Rathnayake D, Sinclair R. Innovative use of spironolactone as an antiandrogen in the treatment of female pattern hair loss. *Dermatol Clinics* 2010; **28**: 611–618.
- 30 Zapacosta AR. Reversal of baldness in a patient receiving minoxidil for hypertension. *N Engl J Med* 1980; **303**: 1480–1481.
- 31 Carlijn H, Sylvia AE, Sinclair R. Treatment of female pattern hair loss with a combination of spironolactone and minoxidil. *Australas J Dermatol* 2007; **48**: 43–45.
- 32 Thai KE, Sinclair RD. Spironolactone induced hepatitis. *Australas J Dermatol* 2001; **42**: 180–182.